

Microcirculatory changes in venous leg ulcers using intermittent electrostimulation of common peroneal nerve

Saroj K Das,¹ Professor, Consultant in Vascular Surgery*; **Luxmi Dhoonmoon,**² Tissue Viability Nurse Consultant; **Duncan Bain,**³ Dr, Biomedical Engineer; **Swati Chhabra,**⁴ Research Team Lead
*Corresponding author email: slam.dunk.bain@gmail.com

1 The Hillingdon Hospital & London North West Health Care NHS Trust, UK. **2** Central and North West Health Care NHS Trust, UK. **3** Bain Consulting, Hertfordshire, UK. **4** London North West University Healthcare NHS Trust, London, UK.

Microcirculatory changes in venous leg ulcers using intermittent electrostimulation of common peroneal nerve

Objective: Activation of the venous muscle pumps of the leg by intermittent transdermal neuromuscular stimulation of the common peroneal nerve has been previously shown to augment venous and arterial flow in patients with leg ulcers. This study aims to establish if microcirculation in the wound bed and periwound area are augmented by the activation of a neuromuscular electrostimulation device (NMES) (Geko, Firstkind Ltd., UK).

Method: In this self-controlled, observational study, laser speckle contrast imaging was used to map and quantify microcirculatory flow in the wound bed and periwound area of patients with venous leg ulcers (VLU). Values of flow and pulsatility in these locations were compared with the NMES device, both active and inactive.

Results: A total of 16 patients took part in the study. Microvascular flux increased by 27% ($p=0.014$) in the wound bed, and by 34% ($p=0.004$) in the periwound area, when the NMES device was activated. Pulsatility increased by 170% ($p<0.001$) in the wound bed and 173% ($p<0.001$) in the periwound area when the device was activated.

Conclusion: Intermittent electrostimulation of the common peroneal nerve substantially increased both microcirculatory flux and pulsatility in the wound bed and in the periwound area of the VLUs of patients in this study. This provides a plausible mechanistic explanation for its reported efficacy in healing VLUs.

Declaration of interest: The authors acknowledge the assistance of Firstkind Ltd., Daresbury, for sponsoring the study.

geko • laser speckle • microcirculation • neuromuscular electrical stimulation • venous leg ulcer • wound • wound bed

The geko device (Firstkind Ltd., UK, Fig 1), powered by OnPulse neuromuscular electrical stimulation (NMES) technology, has been recommended for use in the prevention of deep vein thrombosis (DVT)¹ and leg swelling,² as well as in the treatment of venous leg ulcers (VLUs) and arterial ischaemia.³ VLUs account for approximately 80% of all hard-to-heal leg ulcers,⁴ and are prevalent in close to 1% of the worldwide population.⁵ At the root of the aetiology is chronic venous insufficiency due to occlusion or failure of the venous pump system, leading to elevated ambulatory pressures in the leg, with accompanying macrovascular disturbances and oedema.⁶ Treatment for VLUs is normally based on interventions at the macrovascular level, most commonly compression, which aims to reduce oedema and aid venous return.⁷

Although macrovascular in origin, the mechanism for ultimate skin breakdown is consequent disturbance to the microcirculation, and this facet of the pathophysiology of venous ulceration, long recognised,^{8–10} is now attracting increased attention.

Activation of the calf muscle pumps by means of 1Hz

intermittent neuromuscular stimulation of the common peroneal nerve has been shown to increase not only venous flow, but also arterial and skin microvascular flow^{11,12} and oedema.^{13,14} Electroactivation of the muscle pumps has been used successfully to treat hard-to-heal leg ulcers,^{15,16} and has been shown to deliver a significant increase in healing rate.¹⁷

Although augmentation of venous, arterial and skin microvascular flow provides several viable mechanisms for the NMES device's efficacy in healing wounds, the question remained whether this effect is attended by any augmentation of microvascular blood flow in the wound bed or wound periphery.

Aims

The aim of this study was to determine whether muscle pump activation increased microvascular flow in the wound bed and wound periphery of VLUs.

Methods

Study population

This was a self-controlled observational study with patients with VLUs at Ealing Hospital, which took place over a period of several months in 2019. Patients signed an informed consent form, giving written informed consent to publish case details, including photographs. The study was reviewed and approved by the West Midlands Edgbaston Research Ethics Committee. Patients underwent an examination for vital signs, past medical history and demographics, to screen according

Saroj K Das,¹ Professor, Consultant in Vascular Surgery*; Luxmi Dhoonmoon,² Tissue Viability Nurse Consultant; Duncan Bain,³ Dr, Biomedical Engineer; Swati Chhabra,⁴ Research Team Lead

*Corresponding author email: slam.dunk.bain@gmail.com

¹ The Hillingdon Hospital & London North West Health Care NHS Trust, UK. ² Central and North West Health Care NHS Trust, UK. ³ Bain Consulting, Hertfordshire, UK.

⁴ London North West University Healthcare NHS Trust, London, UK.

to the following criteria:

Inclusion criteria:

- Age: ≥ 18 years
- Intact healthy skin at the site of device application
- Able to understand the Patient Information Sheet
- Willing and able to give informed consent
- Willing and able to follow protocol requirements
- Presence of a hard-to-heal VLU (i.e., clinical-etiological-anatomical-pathophysiological (CEAP) classification of C6 (active venous ulcer)) and <10 cm in maximum diameter

- Ankle-brachial pressure index (ABPI) of ≥ 0.8

- Patient treated with multilayer compression.

Exclusion criteria:

- Wound infection either acute or chronic
- History of significant haematological disorders or DVT within the preceding six months
- Pregnant
- Use of pacemakers or implantable defibrillators
- Use of any other neuromodulation device
- Current use of transcutaneous electrical nerve stimulation (TENS) in pelvic region, back or legs
- Use of investigational drug or device within the past four weeks that may interfere with this study
- Recent surgery that may affect the study (such as, in abdominopelvic or lower limb) in the opinion of the investigator
- Recent trauma to the lower limbs
- Size of leg incompatible with the NMES device
- Obesity (body mass index, BMI >34 kg/m²)
- Any medication deemed to be significant by the investigator
- Patients who had an index VLU greater in maximum diameter than 10cm in any one dimension, or <2 cm
- Diabetes
- Clinical evidence of peripheral arterial disease (i.e., signs or symptoms, in the opinion of the researcher).

Neuromuscular electrostimulation (NMES) device

The NMES (T-2 and R-2) devices are small, disposable, internally powered, neuromuscular stimulators that are applied externally to the leg. The T-2 device has a fixed 27mA current and the R-2 current is fixed at 54mA. The R-2 delivers a higher current to the patient and is intended for patients who do not achieve stimulation (as described below) with the T-2 device. The devices are self-adhesive and are applied to the outer/posterior aspect of the knee. This positioning enables integral electrodes to apply a stimulus to the lateral popliteal nerve (often additionally termed the common peroneal) which branches from the sciatic nerve. This nerve controls the contraction of several muscles in the lower leg. The device is commercially available and CE marked (GB12/87339; SGS, United Kingdom Ltd. Notified Body CE0120).

Microcirculatory flow in both the wound bed and the periwound area were measured using laser speckle contrast imaging (LSCI) (moorFLPI-2TM, Moor Instruments Ltd., UK). This is a non-invasive and

Fig 1. The neuromuscular electrical stimulation device, as applied to the leg. Image reproduced with permission of Firstkind Ltd, Daresbury

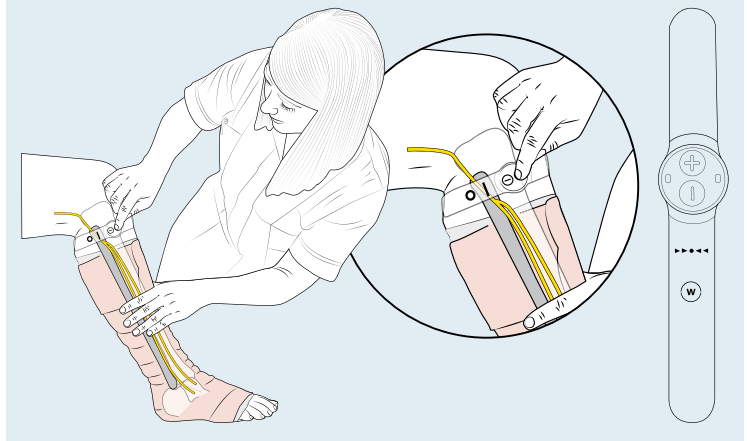


Fig 2. Venous leg ulcer proximal to the malleolus with a clearly delineated wound bed and areas of inflammation, and potential necrosis in the periwound area is shown

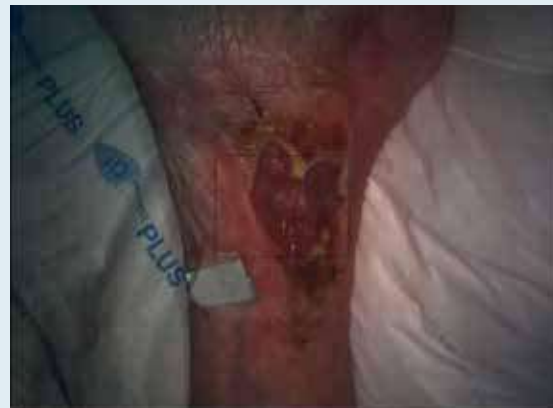

Fig 3. Laser speckle contrast image of the venous leg ulcer shown in Fig 2 with the neuromuscular electrical stimulation device switched off

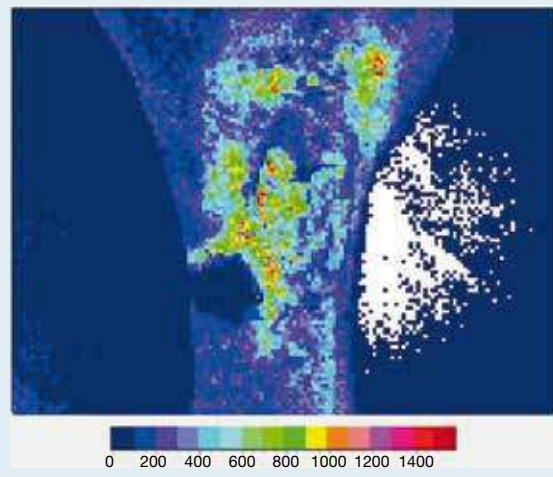
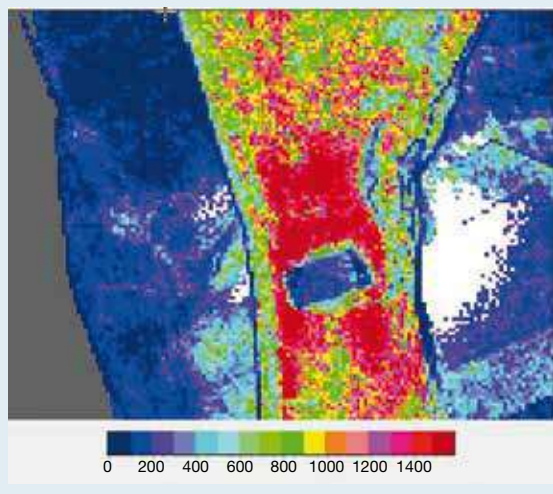


Fig 4. Laser speckle contrast image of the venous leg ulcer shown in Fig 2 with the neuromuscular electrical stimulation device switched on



non-contact technique that is used to measure the changes in microcirculatory flux in the skin or other areas where blood vessels are superficial.¹⁸ Microcirculatory flux, as measured by LSCI, has been shown to be predictive of healing of VLU.¹⁹

Measurement with the NMES device

Each patient was in a recumbent position with the leg outstretched, resting on an evacuated beanbag cushion to immobilise the leg for measurements. A reference marker, consisting of an opaque foil strip, was affixed to the skin adjacent to the wound, to allow for correction of movement artefact.²⁰

The LSCI imager was positioned to record images in

the wound bed, as well as the periwound area, including the reference marker. Measurements were made with the patient at rest, sitting on a trolley, with the leg horizontal at:

- Baseline (following a 10-minute stabilisation period)
- With the NMES device fitted and active for 10 minutes.

Device-on and device-off values for LSCI parameters were compared using paired t-test.

Results

A total of 16 patients took part in the study. Median patient age was 68 years, with an interquartile range (IQR) of 61–79 years. Of the patients, 10 (62.5%) were male and six (37.5%) were female. Median BMI was 27.9kg/m², with an IQR of 25.9–29.5kg/m². All patients were determined by Duplex ultrasound to have venous insufficiency.

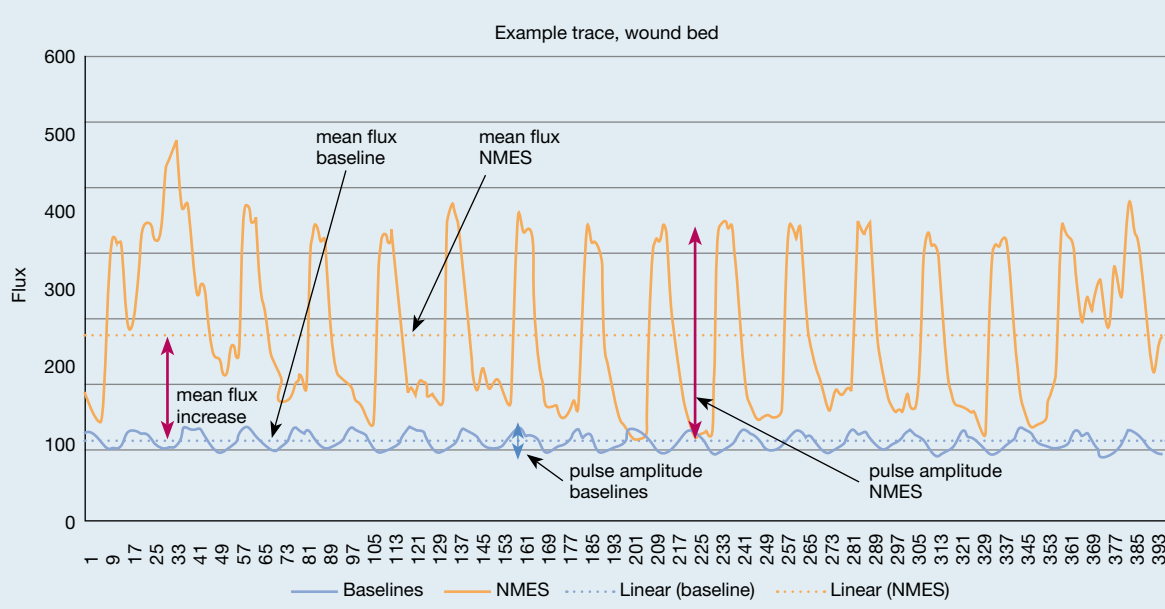
An example VLU, just above the malleolus, with a clearly delineated wound bed and areas of inflammation, and potential necrosis in the periwound area is shown in Fig 2. The perfusion-free reference marker can be seen taped to the leg to the left of the wound.

The LSCI image of the same lower leg with the NMES device switched off is shown in Fig 3. Much of the leg shows very little microvascular perfusion, with only the inflamed areas moderately perfused. The regions of potential necrosis, especially just above the wound (just distal anatomically), shows near-zero perfusion, similar in colour to the reference marker.

Fig 4 shows the effect of the NMES device on the same patient when switched on, with all areas showing a pronounced augmentation in microcirculatory flow, including the wound bed, potentially necrotic areas in the periwound area, and elsewhere on the leg.

An example trace of microcirculatory flux in the

Fig 5. Example trace of flux versus sample counts over a 16 second window. NMES—neuromuscular electrical stimulation device



wound bed for an individual patient is shown in Fig 5. The blue trace shows the baseline (NMES off) flux (arbitrary units), sampled at 25Hz over a 16-second period (400 counts). A pulse of approximately 72 beats per minute (BPM), with a mean flux of 106 arbitrary units, is seen. The pulsatility (pulse amplitude) is approximately 12 units at baseline. When the NMES is switched on (orange trace), a substantial elevation in mean flux from 106 to 224 arbitrary units was observed. Additionally, the pulsatility increases from 12 units to 102 units. As expected, the 'pulse' observed with the NMES on is at precisely 60BPM, since this is the frequency of muscle pump contractions elicited by the NMES.

Mean±standard deviation (SD) values of flux for all patients, in both the wound bed and the periwound area is shown in Fig 6. As with Fig 5, baseline (NMES off) is shown in blue and NMES on is shown in orange. In both the wound bed and the periwound area, NMES produces a substantial and significant ($p=0.014$, $p=0.004$) increase in flux (paired t-test). It must be noted that although the error bars apparently overlap, this predominantly reflects inter-subject variations rather than intra-subject variations, so the paired data still yields significance. NMES has an even more pronounced and highly significant ($p<0.001$, $p<0.001$) effect on pulsatility in both the wound bed and the periwound area (Fig 7).

Discussion

Promising results have been previously reported for the use of NMES in healing VLU. A study in 2017¹⁶ showed significantly increased healing rates in VLUs, with 44% of previously recalcitrant wounds healing and a further 39% decreasing in size within 20 weeks. These results are further supported by case series.^{15,17}

Clearly, electroactivation of the muscle pump results in a considerable increase in perfusion to both the wound bed and to the periwound area. This increase is not only in the form of increased continuous flux, but also in an even greater increase in pulsatility. This is of particular pertinence to wound healing, since pulsatile flow is considered to be vital. Pulsatile blood flow results in shear forces at the endothelial surface and results in chemical signalling and transduction.²¹ This intermittent pressure and velocity in vessels results in forces at the cellular level initiating biochemical changes, including the production of growth factors, nitric oxide production, and the reduction of oxidative stress.²² The stated object of many treatment regimens, including negative pressure therapy, alternating positive pressure therapy, ultrasound therapy, and other energy-based modalities, is to generate pulsatile flow.²³

It has been shown that pulsatile flow prolongs the period of capillary opening before occlusion,²⁴ and that non-pulsatile flow causes a collapse of capillary structure, reduction in blood flow and increase in capillary shunting, irrespective of the mean blood flow and arterial pressure.²⁵ Additional energy delivered to the tissues with pulsatile flow keeps the peripheral

Fig 6. Mean±standard deviation microcirculatory flux with and without the neuromuscular electrical stimulation device (NMES) (all patients). * $p=0.014$; ** $p=0.004$

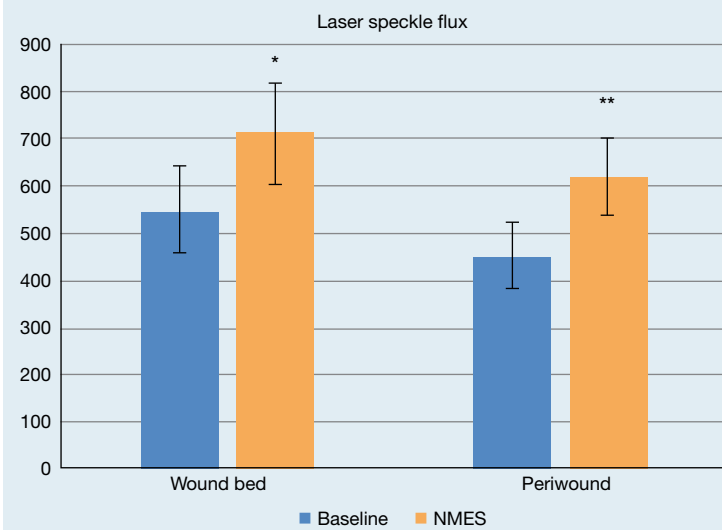
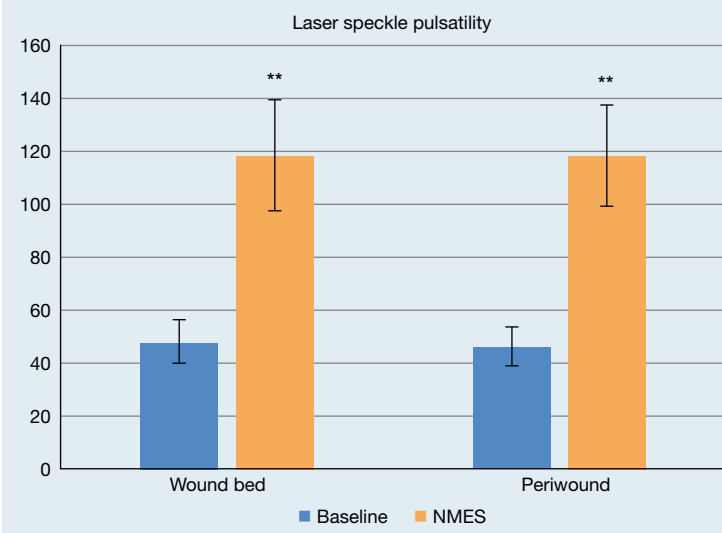


Fig 7. Mean±standard deviation of microcirculatory pulsatility with and without the neuromuscular electrical stimulation device (NMES) (all patients). ** $p<0.001$



circulation open, and promotes extracellular fluid exchange.²⁶ Cyclic motion of blood maintains the concentration gradients required for nutrient exchange, and partial pressure of oxygen (pO_2) transients caused by flow motion oxygenate tissue domains which under steady-state conditions would remain anoxic.²⁷

Limitations

In this study, the effects of compression on the microvascular flow in the wound bed could not be measured, since there is no line of sight from the LSCI device to the wound when the bandaging is in place. Therefore, the authors are not able to make any comparison between NMES and compression in terms

of their effect on the microcirculation in the wound.

This was not a randomised controlled trial, but a measurement of the acute effects of NMES on the microcirculation of the wound in real time. NMES was applied to the patients for approximately 30 minutes, as opposed to several hours daily for several weeks, as per clinical use. No effect on wound healing was expected or observed and patients were not followed up to record healing rates.

References

- 1 National Institute for Health and Care Excellence (NICE). The geko device for reducing the risk of venous thromboembolism. Medical technologies guidance [MTG19]. NICE, 2014. <https://tinyurl.com/y347y29a> (accessed 18 January 2021)
- 2 Wainwright TW, Burgess LC, Middleton RG. A feasibility randomised controlled trial to evaluate the effectiveness of a novel neuromuscular electro-stimulation device in preventing the formation of oedema following total hip replacement surgery. *Heliyon* 2018; 4(7):e00697. <https://doi.org/10.1016/j.heliyon.2018.e00697>
- 3 Williams KJ, Davies AH. The use of a novel neuromuscular electrical stimulation device in peripheral vascular disease. *Int J Case Rep Imag* 2014; 5(11):744–747. <https://doi.org/10.5348/ijcri-201462-CS-10048>
- 4 O'Donnell TF Jr, Passman MA, Marston WA et al.; Society for Vascular Surgery; American Venous Forum. Management of venous leg ulcers: clinical practice guidelines of the Society for Vascular Surgery and the American Venous Forum. *J Vasc Surg* 2014; 60(2 Suppl):3S–59S. <https://doi.org/10.1016/j.jvs.2014.04.049>
- 5 Jindal R, Dekiwadia DB, Krishna PR et al. Evidence-based clinical practice points for the management of venous ulcers. *Indian J Surg* 2018; 80(2):171–182. <https://doi.org/10.1007/s12262-018-1726-3>
- 6 Grey JE, Harding KG, Enoch S. Venous and arterial leg ulcers. *BMJ* 2006; 332(7537):347–350. <https://doi.org/10.1136/bmj.332.7537.347>
- 7 Ratliff CR, Yates S, McNichol L, Gray M. Compression for primary prevention, treatment, and prevention of recurrence of venous leg ulcers. *J Wound Ostomy Continence Nurs* 2016; 43(4):347–364. <https://doi.org/10.1097/WON.0000000000000242>
- 8 McDonagh PF. The microvascular pathophysiology of chronic venous insufficiency. *Yale J Biol Med* 1993; 66(1):27–36
- 9 Puruhito. Pathophysiology of microcirculation in venous disease. *Clin Hemorheol Microcirc* 2000; 23(2–4):239–242
- 10 Jünger M, Steins A, Hahn M, Häfner HM. Microcirculatory dysfunction in chronic venous insufficiency (CVI). *Microcirculation* 2000; 7 S1:S3–S12. <https://doi.org/10.1111/j.1549-8719.2000.tb00145.x>
- 11 Tucker AT, Maass A, Bain DS et al. Augmentation of venous, arterial and microvascular blood supply in the leg by isometric neuromuscular stimulation via the peroneal nerve. *Int J Angiol* 2010; 19(01):e31–e37. <https://doi.org/10.1055/s-0031-1278361>
- 12 Warwick DJ, Shaikh A, Worsley P et al. Microcirculation in the foot is augmented by neuromuscular stimulation via the common peroneal nerve in different lower limb postures: a potential treatment for leg ulcers. *Int Angiol* 2015; 34(2):158–165
- 13 Choi YD, Lee JH. Edema and pain reduction using transcutaneous electrical nerve stimulation treatment. *J Phys Ther Sci* 2016; 28(11):3084–3087. <https://doi.org/10.1589/jpts.28.3084>
- 14 Wainwright TW, Burgess LC, Middleton RG. Does neuromuscular

Conclusions

Intermittent electrostimulation at 1Hz of the common peroneal nerve provides substantial augmentation to the microcirculation in and around the wound bed of VLU, both in terms of continuous flow and pulsatility; this could provide a range of mechanistic explanations for its efficacy in wound healing, in addition to its previously reported augmentative effect on venous and arterial flow. **JWC**

- electrical stimulation improve recovery following acute ankle sprain? A pilot randomised controlled trial. *Clin Med Insights Arthritis Musculoskelet Disord* 2019; 12:1179544119849024. <https://doi.org/10.1177/1179544119849024>
- 15 Jones NJ, Ivins N, Ebdon V et al. Neuromuscular electrostimulation on lower limb wounds. *Br J Nurs* 2018; 27(20):S16–S21. <https://doi.org/10.12968/bjon.2018.27.Sup20.S16>
 - 16 Harris C, Duong R, Vanderheyden G et al. Evaluation of a muscle pump-activating device for non-healing venous leg ulcers. *Int Wound J* 2017; 14(6):1189–1198. <https://doi.org/10.1111/iwj.12784>
 - 17 Harris C, Ramage D, Boloorch A et al. Using a muscle pump activator device to stimulate healing for non-healing lower leg wounds in long-term care residents. *Int Wound J* 2019; 16(1):266–274. <https://doi.org/10.1111/iwj.13027>
 - 18 Mahé G, Rousseau P, Durand S et al. Laser speckle contrast imaging accurately measures blood flow over moving skin surfaces. *Microvasc Res* 2011; 81(2):183–188. <https://doi.org/10.1016/j.mvr.2010.11.013>
 - 19 van Vuuren TM, Van Zandvoort C, Doganci S et al. Prediction of venous wound healing with laser speckle contrast imaging. *Phlebology* 2017; 32(10):658–664. <https://doi.org/10.1177/0268355517718760>
 - 20 Bahadori S, Immins T, Wainwright TW. A novel approach to overcome movement artefact when using a laser speckle contrast imaging system for alternating speeds of blood microcirculation. *J Vis Exp* 2017; (126):56415. <https://doi.org/10.3791/56415>
 - 21 Chen KD, Li YS, Kim M et al. Mechanotransduction in response to shear stress. Roles of receptor tyrosine kinases, integrins, and Shc. *J Biol Chem* 1999; 274(26):18393–18400. <https://doi.org/10.1074/jbc.274.26.18393>
 - 22 Ennis WJ, Lee C, Meneses P. A biochemical approach to wound healing through the use of modalities. *Clin Dermatol* 2007; 25(1):63–72. <https://doi.org/10.1016/j.clindermatol.2006.09.008>
 - 23 Ennis WJ, Meneses P, Borhani M. Push-pull theory: using mechanotransduction to achieve tissue perfusion and wound healing in complex cases. *Gynecol Oncol* 2008; 111(2 Suppl):S81–S86. <https://doi.org/10.1016/j.ygyno.2008.07.054>
 - 24 Burton AC. Relation of structure to function of the tissues of the wall of blood vessels. *Physiol Rev* 1954; 34(4):619–642. <https://doi.org/10.1152/physrev.1954.34.4.619>
 - 25 Takeda J. Experimental study of peripheral circulation during extracorporeal circulation with a special reference to a comparison of pulsatile flow with non-pulsatile flow. *Arch Jap Chir* 1960; 29:1407–1412
 - 26 Shepard RB, Simpson DC, Sharp JF. Energy equivalent pressure. *Arch Surg* 1966; 93(5):730–740. <https://doi.org/10.1001/archsurg.1966.01330050034005>
 - 27 Tsai AG, Intaglietta M. Evidence of flowmotion induced changes in local tissue oxygenation. *Int J Microcirc Clin Exp* 1993; 12(1):75–88

Reflective questions

- How does the neuromuscular electrostimulation device activate the venous muscle pumps of the leg?
- How is microvascular flow in the wound bed increased, and what is its impact on wound healing?
- In what way(s), if any, is pulsatile flow advantageous to wound healing?