

The geko™ Wound Therapy Device: A Case Study Report on Treating Diabetic Foot Ulcers

Authors: Burrows, C., RN, BScN, MScCH (Wound Prevention & Care), Duong, R., RN, BScN, IIWCC, MHA

Aim

To evaluate the impact of the geko™ wound therapy device to treat a Diabetic Foot Ulcer (DFU).

Procedure/Method

- A 69-year-old male with a history of insulin dependent diabetes for 20 years, who had numerous co-morbidities (cardiac, renal, hematologic), developed DFU's secondary to a pressure injury from ill-fitting footwear.
- The left plantar foot ulcers over the 2nd, 4th, and 5th metatarsal heads started in August 2020, and the right plantar foot ulcer started in March 2021. The right foot wound advanced to osteomyelitis and required below knee amputation (BKA) in November 2021.
- The left leg was revascularized at the same time as the amputation and both incisions became infected. The infections were treated successfully with 3 courses of antibiotics. The patient was non-weight bearing and was fitted for off-loading footwear to accommodate a Charcot Foot.
- Homecare nurses then changed dressing 3x/week. Wound treatments included iodine based and silver dressings. In April 2022, the geko™ wound therapy device was added to the treatment plan to treat the DFU's on the left foot, the right BKA stump wound and the left medial calf incision.

References

1. Williams KJ, Davies AH. The use of a novel neuromuscular electrical stimulation device in peripheral vascular disease. *Int J Case Rep Images* 2014;5(11):744–747.
2. Bosanquet D, Ivins N, Jones N, Harding K G, Microcirculatory Flux and Pulsatility in Arterial Leg Ulcers is Increased by Intermittent Neuromuscular Electrostimulation of the Common Peroneal Nerve. Elsevier: Clinical Research 2020 <https://pubmed.ncbi.nlm.nih.gov/32768540/>
3. Das SK, Dhoonmoon L, Chhabra S. Neuromuscular stimulation of the common peroneal nerve increases arterial and venous velocity in patients with venous leg ulcers. *Int Wound J*. 2020;1–7. <https://pubmed.ncbi.nlm.nih.gov/33236847/>

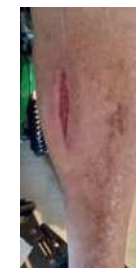
- The geko™ wound therapy device was placed over the fibular head to stimulate the calf and foot muscle pumps and worn for 12 hours per day, 7 days/week.
- The geko™ wound therapy device increases blood flow and decreases edema which promotes wound healing^{1,2,3} The primary caregiver (spouse) was able to apply the geko™ wound therapy device daily. Consent for photos and publication was obtained.

Findings/Results

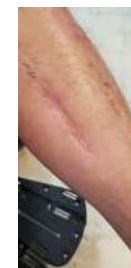- The primary caregiver reported that there was pink tissue in the wounds within the first week of initiating the geko™ wound therapy device.
- In July 2022 the right BKA wound, the left medial calf incision and the left foot ulcers over the 4th and 5th metatarsal head ulcers closed following 8 weeks of geko™ wound therapy when added to standard care.
- The primary caregiver described the geko™ wound therapy device as “easy to use.” While the patient reported “the geko™ wound therapy device was comfortable to wear, and they are very happy with the results.”

Implications/Applications

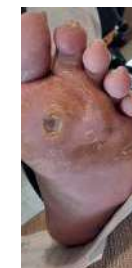- The outcome and potential application of the geko™ wound therapy device in practice is to increase blood flow, reduce edema, decrease time-to-heal, and is user-friendly as described by the primary caregiver.



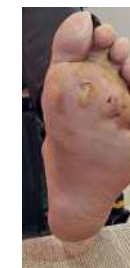Left leg incision open



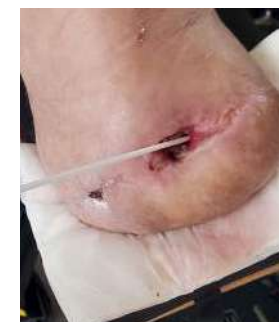Left leg incision July 2022



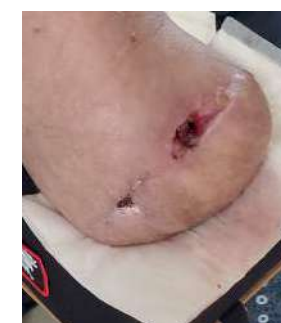Left foot April 2022



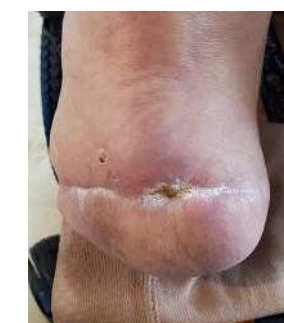Left foot July 2022



Right stump: depth of hole



Right stump July 2022



Right stump September 2022